



**European Society of
MusculoSkeletal Radiology**

Musculoskeletal Ultrasound Technical Guidelines

II. Elbow

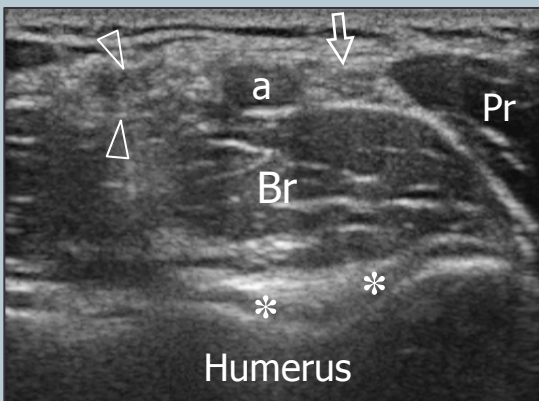
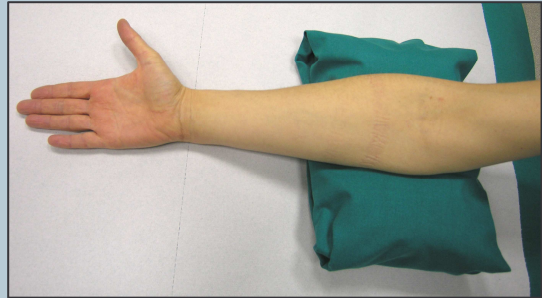
Ian Beggs, UK
Stefano Bianchi, Switzerland
Angel Bueno, Spain
Michel Cohen, France
Michel Court-Payen, Denmark
Andrew Grainger, UK
Franz Kainberger, Austria
Andrea Klauser, Austria
Carlo Martinoli, Italy
Eugene McNally, UK
Philip J. O'Connor, UK
Philippe Peetrans, Belgium
Monique Reijnierse, The Netherlands
Philipp Rempik, Germany
Enzo Silvestri, Italy

Note

The systematic scanning technique described below is only theoretical, considering the fact that the examination of the elbow is, for the most, focused to one quadrant only of the joint based on clinical findings.

1 ANTERIOR ELBOW

For examination of the anterior elbow, the patient is seated facing the examiner with the elbow in an extension position over the table. The patient is asked to extend the elbow and supinate the forearm. A slight bending of the patient's body toward the examined side makes full supination and assessment of the anterior compartment easier. Full elbow extension can be obtained by placing a pillow under the joint.

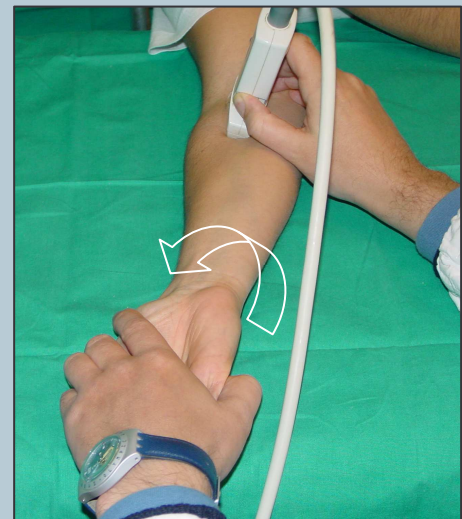


Transverse US images are first obtained by sweeping the probe from approximately 5cm above to 5cm below the trochlea-ulna joint, perpendicular to the humeral shaft. Cranial US images of the supracondylar region reveal the superficial biceps and the deep brachialis muscles. Alongside and medial to these muscles, follow the brachial artery and the median nerve: the nerve lies medially to the artery.

Legend: a, brachial artery; arrow, median nerve; arrowheads, distal biceps tendon; asterisks, articular cartilage of the humeral trochlea; Br, brachialis muscle; Pr, pronator muscle

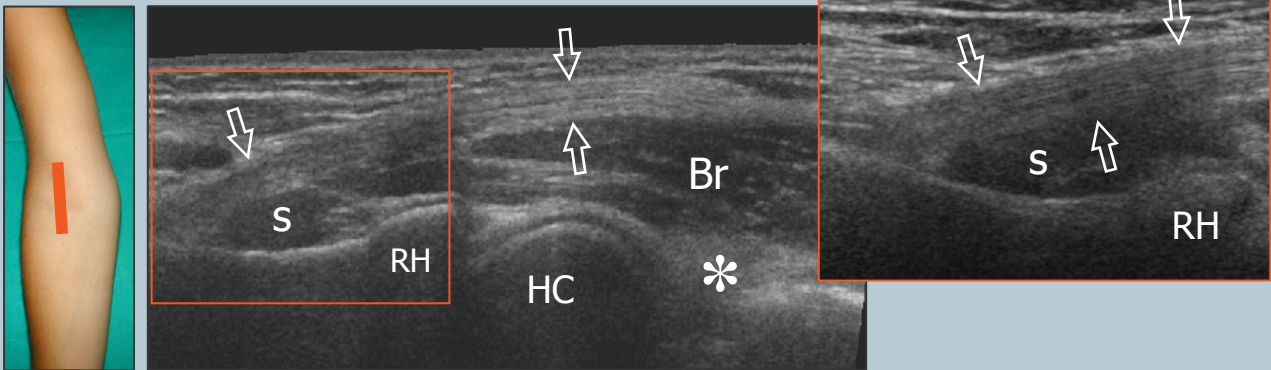
2 distal biceps tendon: technique

The distal biceps tendon is examined while keeping the patient's forearm in maximal supination to bring the tendon insertion on the radial tuberosity into view. Because of an oblique course from surface to depth, portions of this tendon may appear artifactually hypoechoic if the probe is not maintained parallel to it. Accordingly, the distal half of the probe must be gently pushed against the patient's skin to ensure parallelism between the US beam and the distal biceps tendon thus allowing adequate visualization of its fibrillar pattern.



2 distal biceps tendon

The distal biceps tendon is best examined on its long-axis. Short-axis planes are less useful to examine the distal portion of the biceps because slight changes in probe orientation may produce dramatic variation in tendon echogenicity and create confusion between the tendon and the adjacent artery.

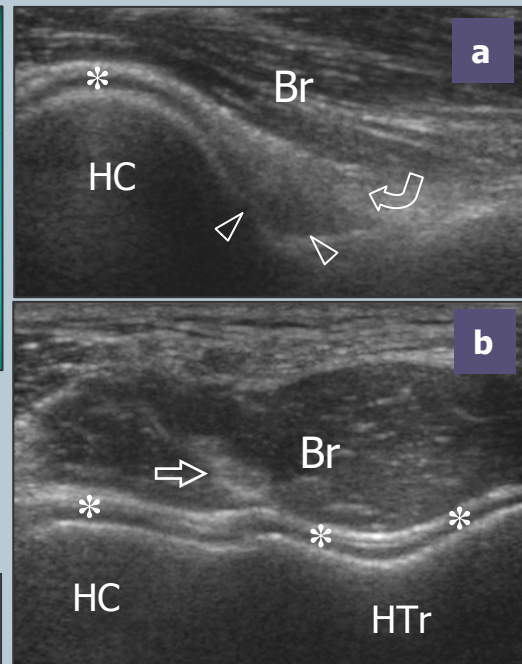
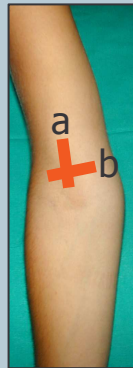

Legend: arrows, distal biceps tendon; asterisk, coronoid fossa and anterior fat pad; Br, brachialis muscle; HC, humeral capitellum; RH, radial head; s, supinator muscle

Follow the short brachialis tendon on long-axis planes down to its insertion on the coronoid process.

3 anterior joint recess

With medial sagittal planes check the coronoid fossa which appears as a concavity of the anterior surface of the humerus filled with the anterior fat pad. In normal states, a small amount of fluid may be seen between the fat pad and the humerus. On transverse scans, the anterior distal humeral epiphysis appears as a wavy hyperechoic line covered by a thin layer of hypoechoic articular cartilage: its lateral third corresponds to the humeral capitellum (round), whereas its medial two thirds relate to the humeral trochlea (V-shaped). On sagittal planes, the radial head exhibits a squared appearance: its articular facet is covered by cartilage.

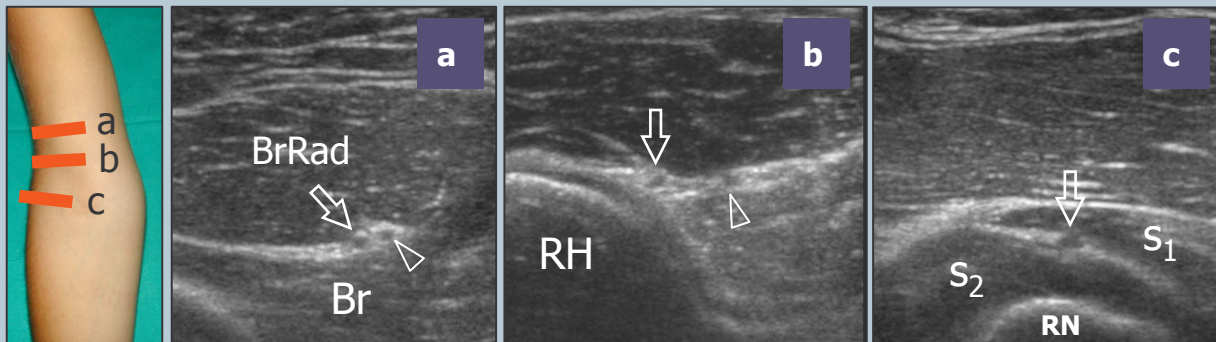
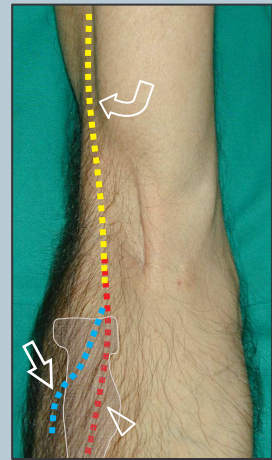


Legend: arrow, brachialis tendon; arrowheads, anterior coronoid recess; asterisks, articular cartilage of distal humeral epiphysis; Br, brachialis muscle; curved arrow, anterior fat pad; HC, humeral capitellum; HTr, humeral trochlea

4 radial and posterior interosseous nerves

Moving to the anterolateral elbow, follow the main trunk of the radial nerve in its short-axis between the brachioradialis and the brachialis muscle down to its bifurcation into the superficial sensory branch and the posterior interosseous nerve. Continue to follow these latter nerves according to their short-axis with meticulous scanning technique. The posterior interosseous nerve must be demonstrated using short-axis planes as it pierces the supinator muscle and enters the arcade of Fröhse passing between the superficial and deep parts of this muscle. Evaluation of the posterior interosseous nerve is made easier by sweeping the probe over the supinator in a transverse plane while performing forearm pronation and supination.

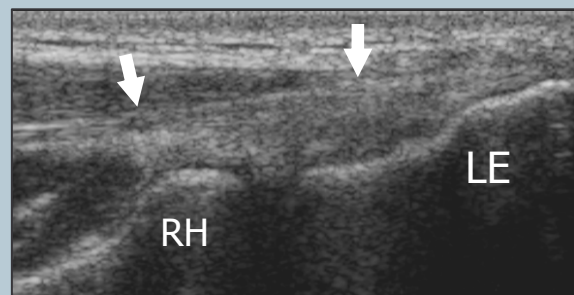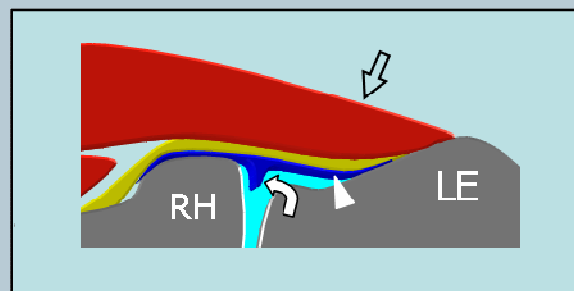
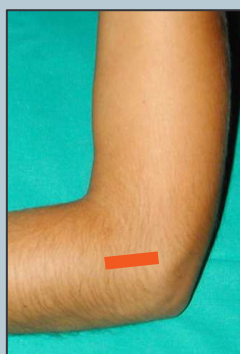
Legend: arrow, posterior interosseous nerve; arrowhead, cutaneous sensory branch of the radial nerve; Br, brachialis muscle; BrRad, brachioradialis muscle; curved arrow, main trunk of the radial nerve; RH, radial head; RN, radial neck; s₁, superficial head of the supinator muscle; s₂, deep head of the supinator muscle



5 LATERAL ELBOW: common extensor tendon

The lateral aspect of the elbow is examined with both elbows in extension, thumbs up, palms of hands together or with the elbow in flexion. The common extensor tendon is visualized on its long-axis using coronal planes with the cranial edge of the probe placed on the lateral epicondyle.

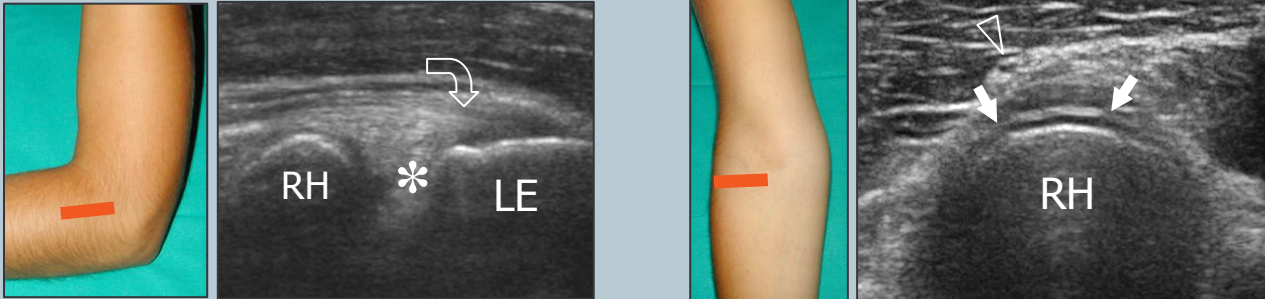
Short-axis planes should be also obtained over the tendon insertion. In normal conditions, the lateral ulnar collateral ligament cannot be separated from the overlying extensor tendon due to a similar fibrillar echotexture.



Legend: arrowhead; lateral ulnar collateral ligament; curved arrow, lateral synovial fringe; LE, lateral epicondyle; RH, radial head; straight arrows, common extensor tendon

6 radiocapitellar joint

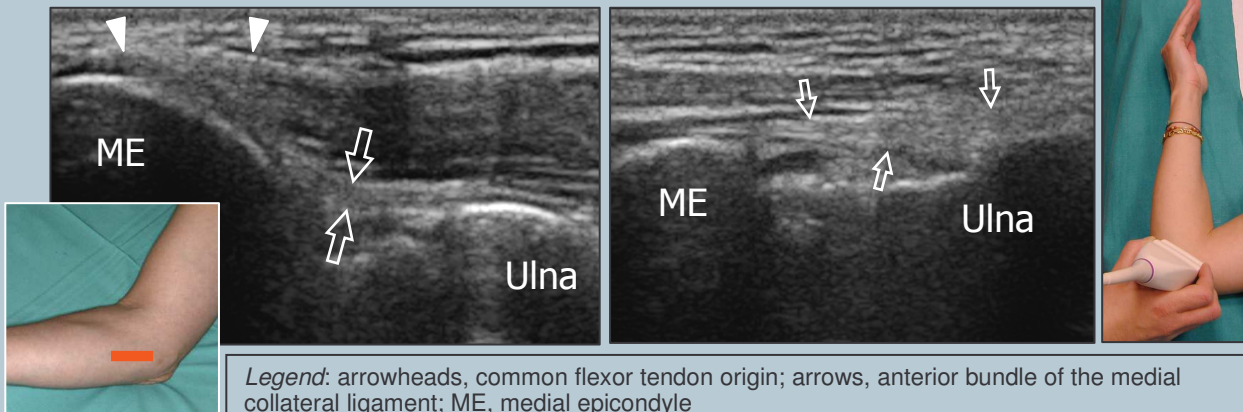
Check the lateral synovial fringe that fills the superficial portion of the lateral aspect of the radiocapitellar joint. Dynamic scanning during passive pronation and supination of the forearm may help to assess the status of the radial head and to rule out possible occult fractures. With this manoeuvre, check the annular ligament. At the radial neck, the annular recess is visible only if distended by fluid.



Legend: arrowhead; posterior interosseous nerve; asterisk, lateral synovial fringe; curved arrow, common extensor tendon; LE, lateral epicondyle; RH, radial head; straight arrow, annular ligament


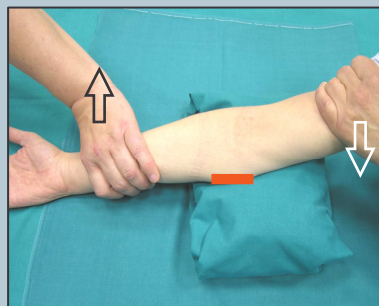
7 MEDIAL ELBOW: common flexor tendon and medial collateral ligament

For examination of the medial elbow, the patient is asked to lean toward the ipsilateral side with the forearm in forceful external rotation while keeping the elbow extended or slightly flexed, resting on a table. Coronal planes with the cranial edge of the probe placed over the medial epicondyle (epitrochlea) reveal the common flexor tendon in its long-axis. The tendon is shorter and larger than the common extensor tendon. Deep to this tendon, check the anterior bundle of the medial collateral ligament.



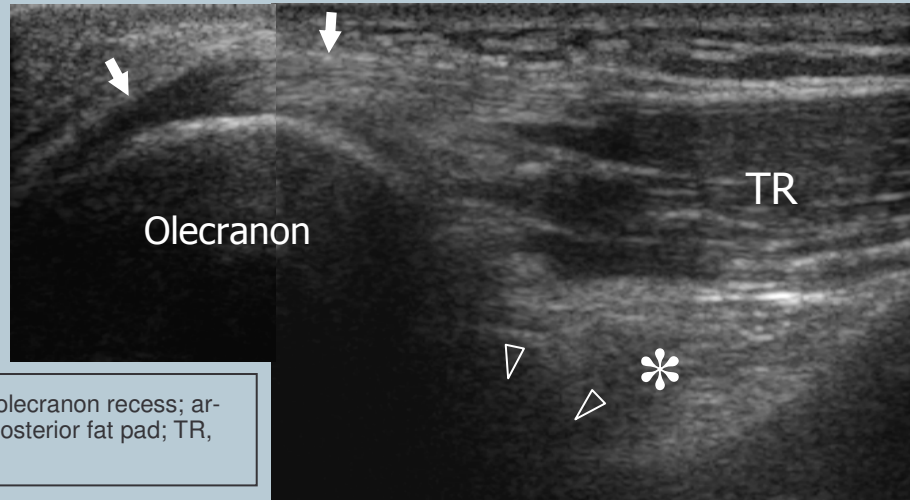
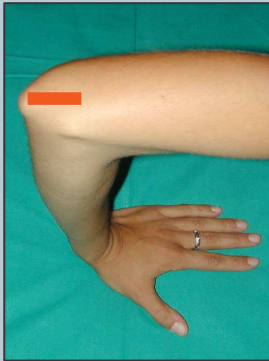
Legend: arrowheads, common flexor tendon origin; arrows, anterior bundle of the medial collateral ligament; ME, medial epicondyle

More adequate positioning for examination of this ligament is obtained with the patient supine keeping the shoulder abducted and externally rotated and the elbow in 90° of flexion. Dynamic scanning in valgus stress (demonstration of joint space widening) may be useful in partial tears, in which the ligament is continuous but lax.



8 POSTERIOR ELBOW: triceps tendon

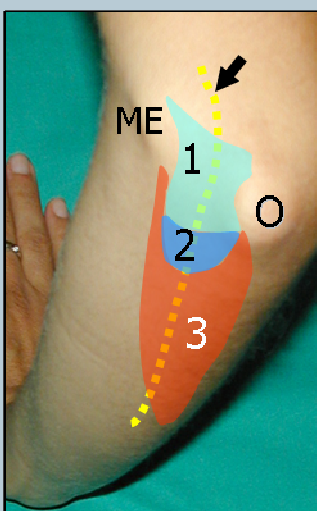The posterior elbow may be examined by keeping the joint flexed 90° with the palm resting on the table. Cranial to the olecranon, the triceps muscle and tendon are evaluated by means of long-axis and short-axis scans. The most distal portion of the triceps tendon needs to be carefully examined to rule out enthesitis.



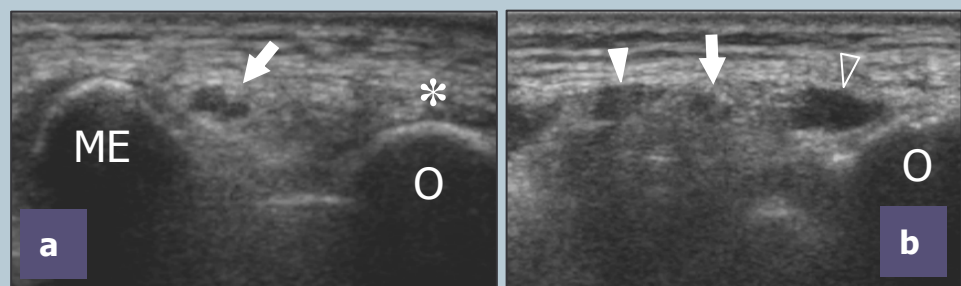
Legend: arrowheads, posterior olecranon recess; arrows, triceps tendon; asterisk, posterior fat pad; TR, triceps muscle

Deep to the triceps, the olecranon fossa and the posterior olecranon recess are evaluated by means of long-axis and short-axis scans. While examining the joint at 45° flexion, intraarticular fluid tends to move from the anterior synovial space to the olecranon recess, thus making easier the identification of small effusions. Gentle rocking motion (backward and forward) of the patient's elbow during scanning may be helpful to shift elbow joint fluid into the olecranon recess. Care should be taken not to apply excessive pressure with the probe when evaluating the superficial olecranon bursa because small bursal effusions may be squeezed away.

9 cubital tunnel and ulnar nerve



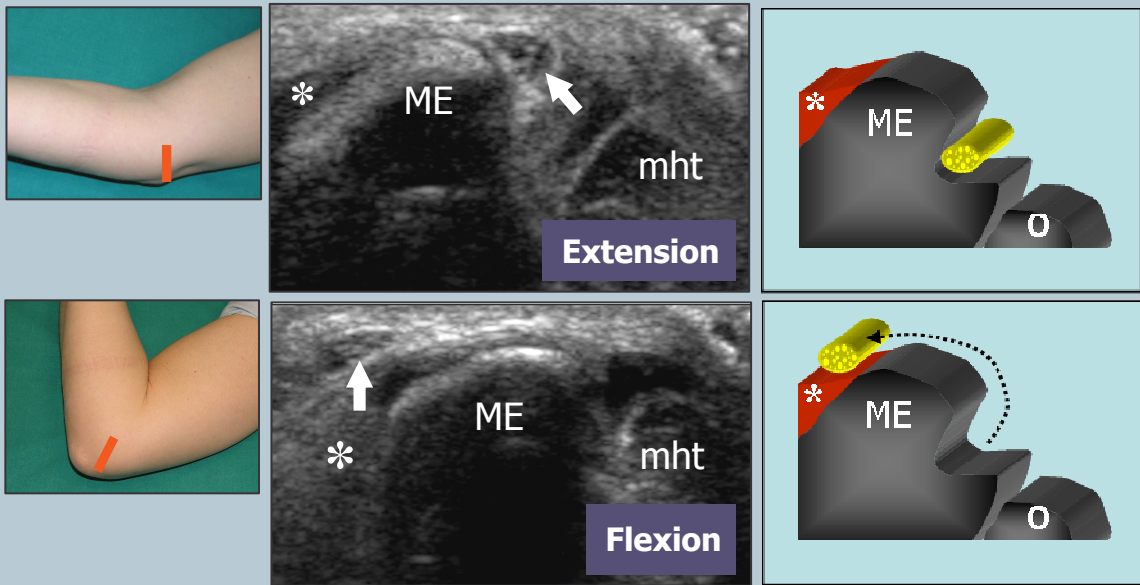
For evaluation of the cubital tunnel, the patient's elbow should be placed in forceful internal rotation with ex-tended elbow (olecranon facing the examiner). The ulnar nerve is examined in its short-axis (long-axis scans are less useful) from the distal arm through the distal forearm. Care should be taken to identify nerve shape changes across the epicondylar groove (a) and the cubital tunnel (b).



Legend: arrow, ulnar nerve; asterisk, triceps tendon; ME, medial epicondyle; O, olecranon process; void arrowhead, ulnar head of the flexor carpi ulnaris muscle; white arrowhead, humeral head of the flexor carpi ulnaris muscle; 1, cubital tunnel retinaculum (Osborne ligament); 2, arcuate ligament; 3, flexor carpi ulnaris muscle

10 ulnar nerve instability

Dynamic imaging of the cubital tunnel is performed either with the patient seated and the elbow placed on a stiff pillow or, at least for the right side, with the patient supine and the arm abducted, hanging out of the table. The position of the ulnar nerve and the medial head of the triceps relative to the medial epicondyle is assessed throughout elbow flexion while placing the probe in the transverse plane with one edge on the olecranon and the other on the medial epicondyle. During this manoeuvre, it should be emphasized that the application of firm pressure on the skin with the transducer must be avoided because it may prevent the anterior dislocation of the nerve from the tunnel.



Legend: Ulnar nerve instability. Arrow, ulnar nerve; asterisk, common flexor tendon; ME, medial epicondyle; mht, medial head of triceps muscle; O, olecranon process. During flexion, the ulnar nerve snaps out of the cubital tunnel. Ulnar nerve instability is related to the absence of the Osborne retinaculum