

REVIEW ARTICLES

Needle-related ultrasound artifacts and their importance in anaesthetic practice

G. Reusz^{1*}, P. Sarkany¹, J. Gal² and A. Csomos²

¹ Department of Anaesthesia and Intensive Care, Markhot Ferenc Hospital, Szechenyi u. 27-29, 3300 Eger, Hungary

² Department of Anaesthesiology and Intensive Care, Semmelweis University, Budapest, Hungary

* Corresponding author. E-mail: reuszgeza@gmail.com

Editor's key points

- Visualizing advancement of the needle is important in ultrasound-guided procedures.
- This paper is a review of needle-related artifacts and how can they be interpreted.
- Importantly, it provides knowledge regarding correct placement of the needle tip and safe practice.

Summary. Real-time ultrasound guidance for any intervention relies on visualization of needle advancement towards a target. Unfortunately, correct identification of the needle tip is not straightforward, as artifacts always distort the image. The ultrasonic appearance of the needle is often degraded by reverberation, comet tail, side-lobe, beam-width, or bayonet artifacts, which can easily confuse an unprepared operator. Furthermore, the typical needle image, that is, a dot or a straight line (out-of-plane and in-plane approaches, respectively), is also a result of artifacts that hide the real dimensions of the needle. Knowledge and correct interpretation of these artifacts is important for safe practice and is paramount to success when precise needle manipulation is mandatory, for example, when the target is small. In this review, authors discuss the most important needle-related artifacts and provide a physical explanation focusing on implications for everyday practice. Recent advances that allow increased needle visualization and reduction of artifacts are also discussed.

Keywords: artifacts; needles; ultrasonography, interventional; patient safety; vascular access devices

Ultrasound is now commonly used in anaesthetic practice as a guidance tool for invasive procedures. In most cases, the procedure involves a needle advancing towards a target; the procedure could be either a regional block needle insertion or a catheter insertion. Several studies showed that real-time visual control of needle manipulation increases the safety of the intervention, and consequently, recent guidelines highly recommend ultrasound guidance for a variety of applications.^{1–6} The needle tip may cause complications, so its visualization throughout the procedure is crucial to avoid complications.

Exact identification of the needle tip is not straightforward partly because artifacts (i.e. any perceived distortion caused by the instrument of observation) always obscure the picture.⁷ When the target is large, this is usually not a problem, but the correct interpretation of the image becomes increasingly more important when the target is smaller, in the case of regional anaesthetic blocks.

Some of the artifacts are virtually always present as they are based on the physical limits of ultrasound imaging, that is, common artifacts. Some other uncommon artifacts only occasionally distort the image, but when they do, it can be very confusing to an unprepared operator.

Physical background of needle imaging and common ultrasound artifacts

The needle shaft is a fine-bore metal tube; its transverse section is a circle and the longitudinal section consists of two walls (i.e. anterior and posterior needle walls) with a lumen in between. On the ultrasound image, however, the needle typically appears as a dot (out-of-plane technique) or one long line (in-plane technique), and is best identifiable when aligned parallel to the probe; visualization becomes poor at large insertion angles. The difference between the visual and the ultrasound appearance of the needle can be explained by three physical concepts: resolution, reflection, and acoustic shadowing.

Resolution

In an image, spatial resolution is defined as the ability to distinguish two objects very close together in space⁸ (not to be confused with temporal resolution, which is related to the frame rate and is not applicable to still images). Spatial resolution can be further sub-categorized into axial resolution (along the axis of the ultrasound beam) and lateral resolution (perpendicular to the beam). There is a misconception that

ultrasound resolution is insufficient to make a distinction between the two walls of the needle shaft, and it is not always true.

The axial resolution of the ultrasound theoretically equals half of the pulse length.⁹ As the width of the ultrasound pulse, which is emitted by the transducer, is typically 1–3

wavelengths, the resolution is ~ 1 wavelength. This can be calculated by dividing ultrasound velocity (1540 m s^{-1} in soft tissues) by its frequency; it means that at 10 MHz the resolution limit in soft tissues is $\sim 0.15 \text{ mm}$. As needle diameter is in the order of 1 mm (e.g. 0.9 and 1.6 mm for a 20 and a 16 G needle, respectively), the resolution of modern ultrasound machines is sufficient to see the structure of the needle, that is, to show both the anterior and posterior needle walls with a lumen in between. In fact, in contrast to metal needles, both walls of plastic catheters are usually identifiable (Fig. 1).

Reflection

The ultrasound beam is reflected back at tissue interfaces; this is crucial to ultrasound imaging, as to be able to show an object, the transducer must receive an echo from its surface and contents. Rough surfaces scatter the ultrasound to all directions and the exact orientation does not have a large impact on picture quality. In contrast, very smooth surfaces, for example, metal needles and cannulas, behave like a mirror and the reflected ultrasound travels in a straight line. This is called specular reflection and similarly to light, the angle of incidence equals the angle of reflection.^{9 10} Furthermore, smooth surfaces are best seen when the angle of incidence is zero (i.e. the ultrasound beam is perpendicular to the surface), but visualization of traditional needles becomes poor at steep insertion angles (Fig. 2A and B).¹¹

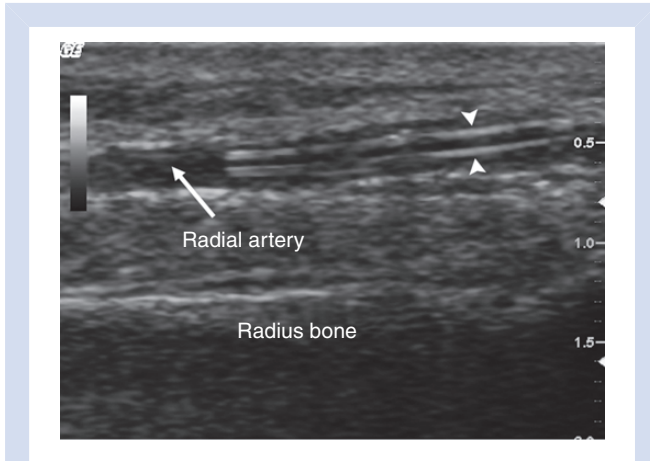


Fig 1 A 20 G arterial cannula in the radial artery (long-axis view). In contrast to needles, both the anterior and the posterior walls of the plastic cannula are clearly recognizable (arrowheads) and there is no image distortion below the catheter.

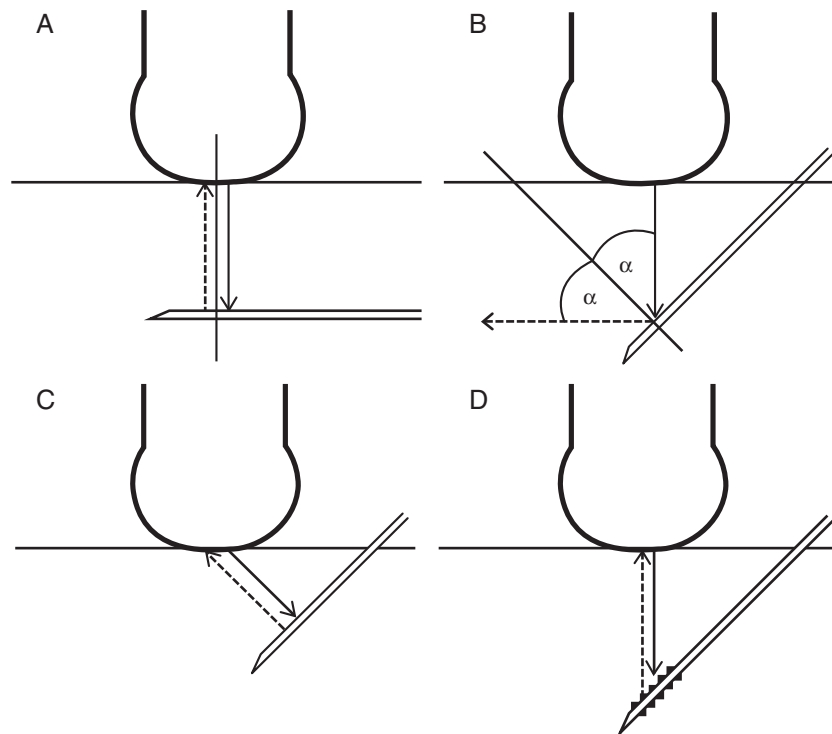


Fig 2 Specular reflection from the needle. The angle of incidence equals the angle of reflection. Visualization is best when the angle of incidence is zero (A) but becomes poor at steep insertions because the echoes are reflected away from the transducer (B). Beam steering (C) and echogenic needles (D) overcome this problem—see explanation later in text under ‘Advanced two-dimensional imaging’ (C) and ‘Echogenic needles’ (D).

Table 1 Acoustic impedance of various tissues and materials^{13 14}

	Acoustic impedance (rayl)
Air	0.0004
Fat	1.34
Blood	1.65
Muscle	1.71
Teflon (PTFE)	2.97
Bone	7.8
Stainless steel	45.7

Clinical importance

Care must be taken to decrease the angle of incidence (i.e. align the needle parallel to the probe) as much as possible by choosing an appropriate needle entry site and occasionally by tilting the opposite end of the ultrasound probe down ('heel in' manoeuvre).¹²

Acoustic shadowing

The ratio of reflected and transmitted ultrasound is determined by the difference in acoustic impedances of tissues on either side of the interface: the larger the difference, the more ultrasound is reflected back. Acoustic impedances of soft tissues are very similar to each other (Table 1); the reflected ultrasound at soft tissue interfaces is $\leq 1\%$, just enough to produce detectable echoes.¹⁰ Bone has much larger acoustic impedance; consequently, soft tissue and bone interfaces give a very strong echo. Unfortunately, this makes the examination of underlying objects impossible, as only a small percentage of the original ultrasound energy remains available for deeper planes. This phenomenon is called acoustic shadowing and is one of the most common ultrasound artifacts. Air prevents ultrasound scan for the same reason.

Acoustic impedance of most plastics is relatively close to soft tissues; this is why plastic catheters do not cause acoustic shadowing and do not obscure the image (Table 1). Metal needles, however, have very high acoustic impedance and behave similarly to bone; they give a very strong echo and appear as a bright (hyper-echoic) line on the image. In contrast to bone, the acoustic shadow of the needle is not very obvious because of the small dimensions and it is usually neither wide nor deep enough to distort the whole image (but it can happen, see Fig. 3). However, the posterior wall of the needle shaft, which is very close to the highly reflective anterior wall, is obscured.¹⁵ This is why we typically see only one line as the representation of the needle on the image, that is, the anterior wall. Unfortunately, the real dimensions of the needle are consequently hidden.

Needle bevel and position of needle tip

To obtain a sharp point, the distal end of the needle is cut obliquely, typically at angles 15–20° (i.v. cannulas) or 30° (block needles), and the needle tip is at the most distal point of this bevel. The bevel length is determined by two factors: the

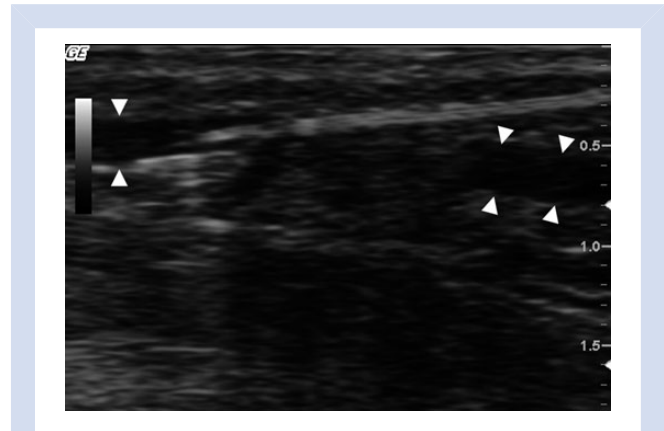


Fig 3 Peripheral i.v. access with an 18-G cannula, in-plane approach. Observe that the middle portion of the vein is invisible and underlying tissues appear darker owing to acoustic shadow of the introducer needle (long bright line coming from the top-right corner of the image and entering the vein). Visible parts of the vein are indicated with arrowheads.

diameter of the needle and the cut angle; for example, it is ~ 1 mm for a 22 G short-bevel block needle, and is as long as 4–6 mm for a 16 G hypodermic needle, potentially detectable by ultrasound.

The orientation of the needle bevel has an impact on the ultrasound image of the needle tip, especially when using in-plane technique and standard (long-bevel) i.v. cannulas. When the bevel faces downwards (needle tip up) there is typically only one long line on the image, as discussed above; the needle tip is at the distal end of this line. However, when the bevel faces upwards, another short line can be observed in front and below the main needle line (Fig. 4). We showed this is not an artifact but part of the needle: the distal end of the posterior needle wall—uncovered by the anterior wall—gets out of the acoustic shadow at the bevel and is recognizable.¹⁵ The tip of the needle is at the distal end of this short 'bevel line'.

Clinical importance

In-plane technique is technically demanding, as the operator has to manipulate with the needle in a very thin plane. If the needle tip leaves this plane, the distal end of the needle line on the image does not correspond to the tip, but to a more proximal part of the shaft, risking accidental puncture of vital organs if unrecognized. The bevel line can be used as a direct visual confirmation of the needle tip; furthermore, as it is best seen when the tip is exactly in the plane of the ultrasound, it can be a useful guide to keep the needle central throughout the procedure.

The bevel length needs to be taken into consideration when cannulating small vessels such as peripheral veins and arteries; for example, the average diameter of the radial artery is 2.5 mm.¹⁶ In these cases, the exact identification of the needle tip (i.e. the distal end of the bevel line) is important in order to facilitate intravascular placement of the cannula.

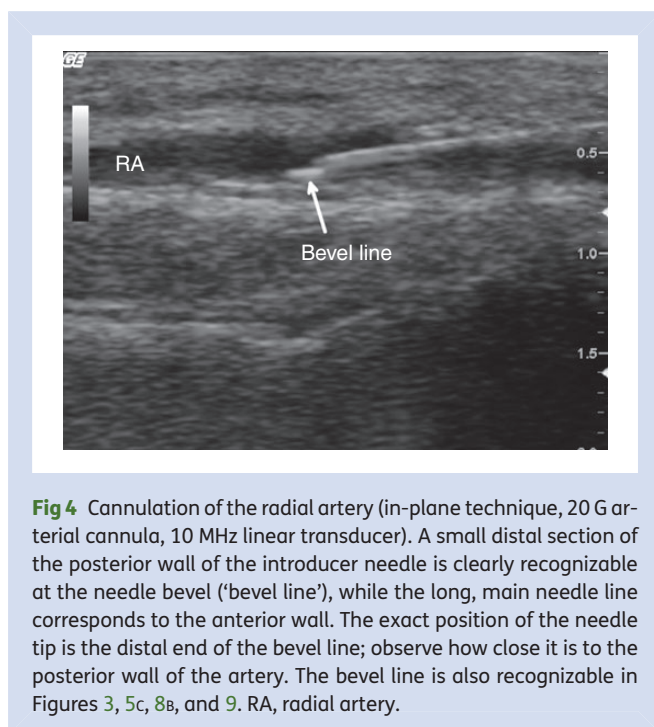


Fig 4 Cannulation of the radial artery (in-plane technique, 20 G arterial cannula, 10 MHz linear transducer). A small distal section of the posterior wall of the introducer needle is clearly recognizable at the needle bevel ('bevel line'), while the long, main needle line corresponds to the anterior wall. The exact position of the needle tip is the distal end of the bevel line; observe how close it is to the posterior wall of the artery. The bevel line is also recognizable in Figures 3, 5c, 8b, and 9. RA, radial artery.

Variations of needle-related ultrasound artifacts

Reverberation artifact

Although usually most of the ultrasound energy is reflected back from the anterior needle wall, occasionally some ultrasound penetrates the anterior wall and the beam gets into the shaft. As the shaft consists of two parallel, very reflective walls, the ultrasound gets 'trapped' within the shaft by bouncing back and forth between the two walls, giving reverberation artifacts on each reflection (Fig. 5A).^{17 18} They appear as multiple parallel lines; the distance between consecutive lines is fixed and equals the diameter of the needle. Logically, in the absence of two parallel surfaces, there is no reverberation at the needle bevel (Fig. 5B and C).

Clinical importance

Reverberation artifacts can considerably confuse the whole image. It is important to know that the first two lines correspond to the anterior and posterior walls of the needle shaft, and only the subsequent lines are artifacts. Consequently, the needle tip is at the distal end of the first or second line, depending on bevel orientation.

Comet tail sign

The comet tail sign was described as a form of reverberation artifact caused by very small objects that are bordered by reflective surfaces; the theory behind is the same as above, but because of the small size of the object, the artifact appears only as a vertical line or 'tail' under the source.^{19 20} A similar artifact can also be observed under needles (and also

guidewires) in the short-axis view. The reverberation is within the lumen of the needle, as described above.

Clinical importance

Although the 'tail' can penetrate deep down, the needle itself is located at the upper end of the tail; the rest of the vertical line is only artifact and as such cannot cause any harm even when apparently cutting into sensitive areas (Fig. 6).

Beam-width and side-lobe artifacts

The ultrasound transducer consists of several piezo crystals arranged in a row and ideally, each crystal provides information about only one vertical line below the element. The ultrasound image is a reconstruction of these elemental lines into a two-dimensional picture ('B' mode). Unfortunately, in reality the ultrasound beam emitted by a crystal is not a one-dimensional line, but has a three-dimensional shape: the beam is narrowest at the focal zone but gets wider at deeper planes. The machine cannot differentiate between reflections from the central and peripheral parts of the beam, which has two disadvantageous consequences: (i) the lateral resolution is limited by the beam width (and is consequently greatest at the focal zone, but is poor at deep planes). (ii) At deep planes, the beams of neighbouring crystals can overlap each other and the reception field of a crystal can extend to neighbouring areas. Strong reflectors, such as needles, can 'activate' crystals that are not immediately above but more lateral from the object, and this leads to incorrect visualization.²¹

Side-lobe artifacts are very similar to beam-width artifacts. Apart from the main vertical ultrasound beam or 'lobe' that carries the relevant information, some other side lobes, running obliquely, are also generated in the transducer. The energy level of these side lobes is much lower, but, with a similar mechanism to beam-width artifacts, it may be enough to produce faulty images if highly reflective surfaces are nearby (Fig. 7).^{21 22}

Clinical importance

Because of side-lobe and beam-width artifacts, the apparent position of a strongly reflective object, for example, the needle tip, on an ultrasound image can be more lateral than the real location. It can happen that the virtual position of the needle tip is in a sensitive area (e.g. nerve or vessel), while in fact this is only the artifact and the injection could be safe.²² On the other hand, during vascular access, the needle tip may already appear intravascular, but aspiration is impossible, as the real needle tip is still out of the vessel.

To avoid beam-width artifacts (and also optimize lateral resolution), it is important to set the focus point at or slightly below the target. Unfortunately, side-lobe artifacts cannot be diminished with simple ultrasound setting.

Bayonet artifact

This is a virtual bending of the straight needle caused by faulty image processing. To show an object at a correct place on the

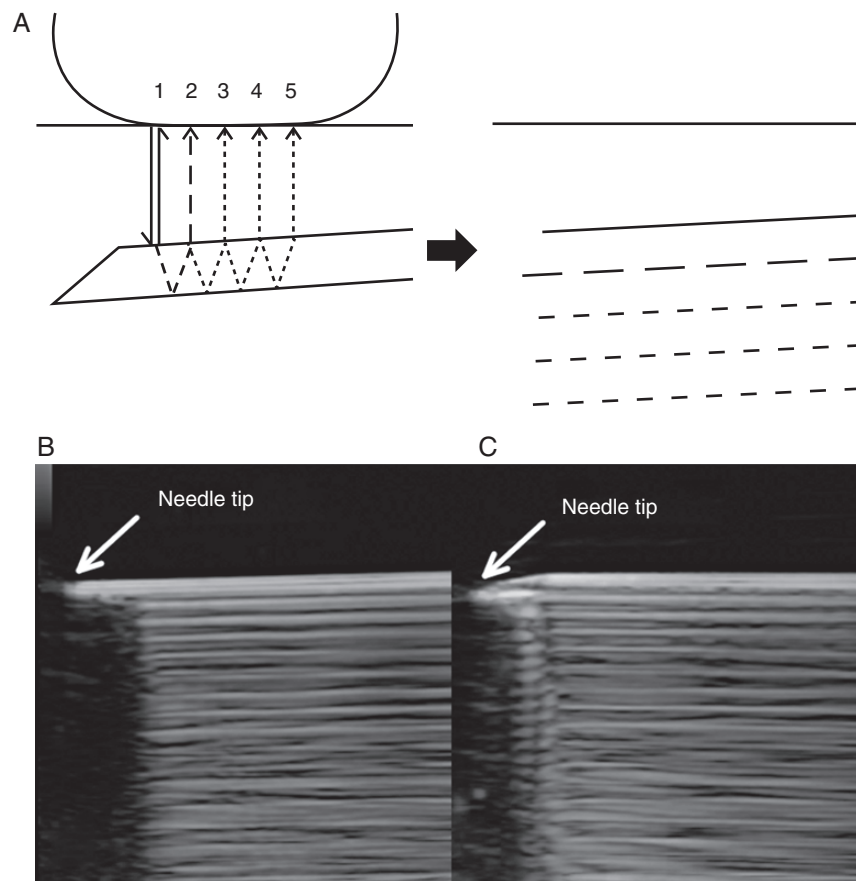


Fig 5 (A) Mechanism of reverberation artifacts. They are generated as to-and-fro reverberations of the ultrasound beam between the anterior and the posterior needle walls. The first and second lines correspond to the needle walls, and only the subsequent lines (Lines 3–5 in the illustration) are artifacts. (B and C) Reverberations caused by a 18 G hypodermic needle in a water bath. There is no reverberation at the needle level, but only in the shaft. The exact position of the needle tip depends on bevel orientation [(B) bevel down, (C) bevel up].

image, the ultrasound machine calculates its depth below the transducer. This is done by multiplying echo return time (measured) with ultrasound speed (assumed). The software of the machine assumes a constant ultrasound speed (1540 m s^{-1}) in soft tissues; however, this is an average value and the actual speed can be slightly different. When the needle goes through or under tissues with different characteristics, the reflected ultrasound beam from different parts but the same depth of the needle arrives back to the probe at slightly different times. This confuses image processing, causing degraded images (Fig. 8).^{23 24}

Strategies to reduce/bypass artifacts and increase needle visualization

Three-dimensional techniques

The needle tip is advanced towards its target in a three-dimensional space, and with traditional two-dimensional ultrasound, it is not easy to keep track of its position during advancement. *Real-time three-dimensional ultrasound*, also called four-dimensional ultrasound, can theoretically

overcome this problem by giving a continuous three-dimensional image during the intervention. Unfortunately, at present, technical limitations hinder the spread of this technique. Compared with the traditional two-dimensional ultrasound, much more data are needed for the construction of a three-dimensional image; at present, this can only be achieved with a bulky transducer, reduced image quality, or both (reduced resolution and slower frame rate).^{25 26}

Another strategy is to use a *needle-positioning system* with a dual-modality imaging device. A standard two-dimensional ultrasound is combined with three-dimensional position sensors such as electromagnetic sensors that are mounted on both the transducer and the needle tip. These sensors enable the device to determine actual needle tip position in relation to the transducer, and superimpose this information on the ultrasound image, showing exactly where the needle is going, even when it is out of the plane of the ultrasound beam.²⁷

These instruments have been designed to facilitate needle manipulation in the three-dimensional space, but not to reduce artifacts; however, needle-positioning systems bypass ultrasound artifacts by using a second modality for needle tip

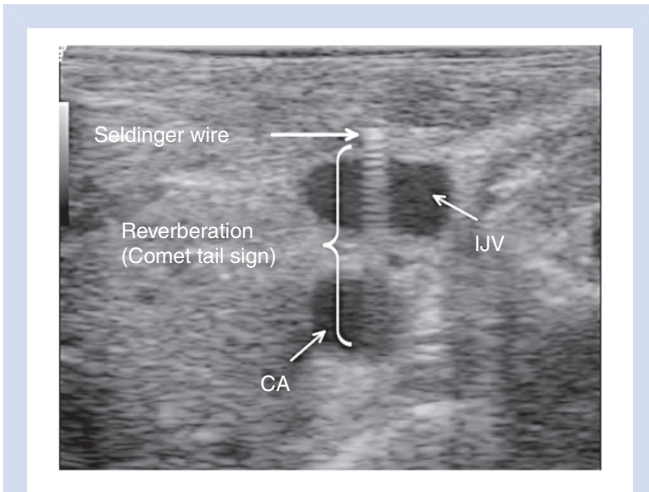


Fig 6 Short-axis view of a Seldinger wire a few millimetres above its entry to the jugular vein. In this plane, the wire is still in the tissues even though reverberation artifacts run into the vein and the artery on the image ('comet tail' sign). The same artifact can be observed under needles (see also Fig. 7). IJV, internal jugular vein; CA, carotid artery.

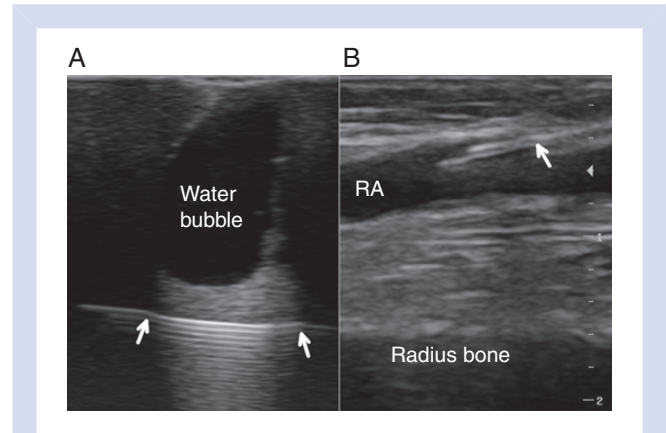


Fig 8 (A) Virtual bending of the needle below the edges of a water bubble in a phantom (arrows) called 'bayonet' artifact. (B) Cannulation of the radial artery using in-plane technique (20 G over-the-needle arterial cannula, 10 MHz linear transducer). Bayonet artifact is indicated by an arrow. RA, radial artery.

detection. Time will reveal whether these innovative new technologies will gain popularity in the future.

Advanced two-dimensional imaging

Visualization of needles inserted at steep angles becomes poor owing to specular reflection, as discussed above. A solution to this problem is *beam steering*, that is, altering the angle of the transmitted ultrasound beam mechanically or electronically (so that the beam direction is more perpendicular to the needle). In these 'needle frames', more ultrasound is reflected back towards the probe, which allows better needle visualization (Fig. 2c). Modern transducers are capable of producing and accepting ultrasound beams at many different angles and the ultrasound machine combines the echoes from different directions into a single composite frame (*compound spatial imaging* or *multi-beam imaging*). Spatial compound images are of better quality compared with conventional ultrasound: there is improved contrast resolution and less noise on the image.²⁸ Although technically difficult, it is theoretically possible to combine frames or 'imaging signatures' that are individually optimized to see either tissues (e.g. with vertical beam direction) or needles (with beam steering); sophisticated image-processing algorithms have recently been developed and are now available on ultrasound machines, which allow enhanced visualization of the needle while maintaining good overall image quality (Fig. 9).^{29 30}

Frequency compound imaging (detection of the signal at different frequency bands within the transmitted spectrum to produce a combined image) is another option for noise reduction, but does not seem to have a significant effect on needle visualization.¹² *Tissue harmonic imaging* is based on detection of harmonic frequencies (multiples of the transmitted ultrasound frequency) that are generated in the body as the ultrasound wave insonates tissues.³¹ Harmonic beams are narrower than the fundamental beam, which results in improved

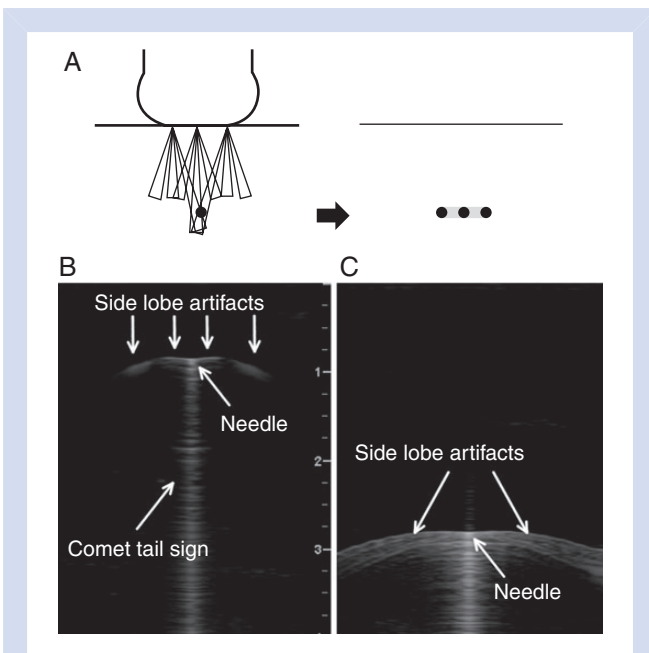


Fig 7 (A) Mechanism of side-lobe artifacts. The object is in the main lobe of the middle transducer crystal, but is also sensed by neighbouring crystals via side lobes, which leads to image duplication. (B and C) Side-lobe artifacts caused by a single 18 G hypodermic needle in a water bath (short-axis view). The horizontal lines on the either side of the needle are side-lobe artifacts, whereas the vertical line below it is a comet tail sign; the needle itself is at the junction (B). Side-lobe artifacts become more extensive as depth increases because the diverging side lobes overlap each other more (C). In real life, this artifact is not so significant, thanks to attenuation of side-lobe energy in tissues; however, the apparent needle tip position on the image can be inaccurate.

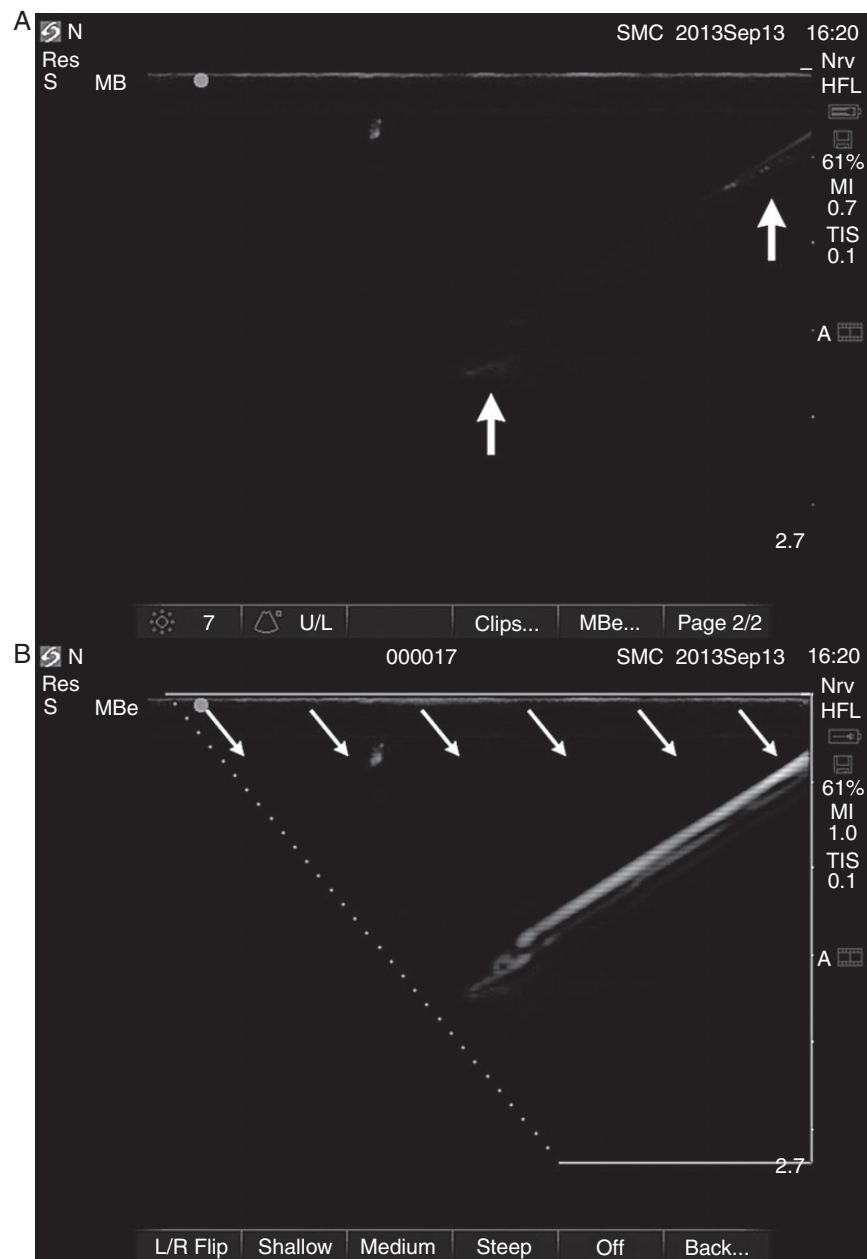


Fig 9 Software-enhanced visualization of a hypodermic needle in a phantom (Sonosite Edge ultrasound machine, SonoSite Inc., Bothell, WA, USA). (A) When enhanced needle visualization (ENV) is off, the needle is hardly recognizable even though it is perfectly in the plane of ultrasound, as echoes can be detected both at the proximal shaft and at the tip (arrows). (B) When ENV is on, a needle frame, optimized for needle visualization, is superimposed on the original image. Thanks to beam steering (indicated by arrows) and software enhancement, the needle is clearly seen even at a steep angle. Note that, because of the oblique beam direction, the needle frame covers only part of the primary image; the edge of the active area is indicated by a dotted line on the screen.

lateral resolution and a reduction of side-lobe artifacts, but needle visibility seems to be compromised.^{32 33}

Echogenic needles

Echogenic needles are also designed to enhance needle visualization, especially at steep insertion angles. They either have an echogenic coating or contain several specially designed tiny

reflectors crafted in the needle material that reflect ultrasound towards the transducer (Fig. 2D, Fig. 10).^{34 35} A variety of echogenic regional block needles and also echogenic central venous catheter sets are commercially available.^{36–38}

A different strategy is an ‘active’ needle tip design. In one set-up, a tiny piezoelectric sensor, placed at the needle tip and activated by ultrasound waves, sends electric impulses

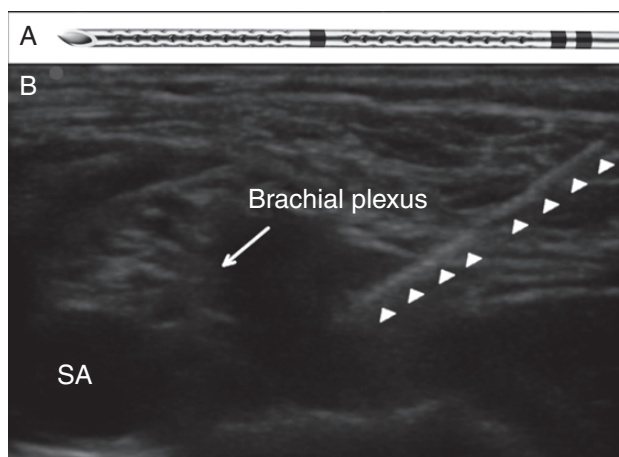


Fig 10 (A) Echogenic needle containing several tiny reflectors crafted in the needle wall, arranged in two strips at the distal part of the needle (Pajunk sonoline regional block needle, Pajunk Medical Produkte GmbH, Geisingen, Germany). (B) Supraclavicular block. The two strips of the approaching needle, containing the reflectors, are easily recognizable (arrowheads) despite the steep angle. SA, subclavian artery.

towards the ultrasound machine, which subsequently displays needle tip position.³⁹ Another device creates low-frequency vibrations in a piezoelectric actuator placed at the tip of the needle; in this case, colour Doppler mode of a two-dimensional ultrasound is used to detect vibrations, that is, needle tip position.⁴⁰ These systems are not in common use.

Conclusions

Identification of the needle, and especially the needle tip, is crucial during ultrasound-guided interventions. Unfortunately, image artifacts obscure the dimensions of the needle and occasionally considerably distort the whole image. Knowledge and correct interpretation of these artifacts is important for safe practice and is paramount to success when precise needle manipulation is necessary, for example, when the target is small.

Authors' contributions

The review was conceived by G.R., A.C., and J.G. The ultrasound was performed and images were collected by G.R. and P.S. Literature review was done by G.R. Manuscript preparation was done by G.R. and A.C., and reviewed by P.S. and J.G.

Declaration of interest

None declared.

References

- Karakitsos D, Labropoulos N, De Groot E, et al. Real-time ultrasound-guided catheterisation of the internal jugular vein: a prospective comparison with the landmark technique in critical care patients. *Crit Care* 2006; **10**: R162
- Fragou M, Grawanis A, Dimitriou V, et al. Real-time ultrasound-guided subclavian vein cannulation versus the landmark method in critical care patients: a prospective randomized study. *Crit Care Med* 2011; **39**: 1607–12
- Shiloh AL, Savel RH, Paulin LM, Eisen LA. Ultrasound-guided catheterization of the radial artery: a systematic review and meta-analysis of randomized controlled trials. *Chest* 2011; **139**: 524–9
- Perlas A, Lobo G, Lo N, Brull R, Chan VW, Karkhanis R. Ultrasound-guided supraclavicular block: outcome of 510 consecutive cases. *Reg Anesth Pain Med* 2009; **34**: 171–6
- Lamperti M, Bodenham AR, Pittiruti M, et al. International evidence-based recommendations on ultrasound-guided vascular access. *Intensive Care Med* 2012; **38**: 1105–17
- Troianos CA, Hartman GS, Glas KE, et al. Guidelines for performing ultrasound guided vascular cannulation: recommendations of the American Society of Echocardiography and the Society of Cardiovascular Anesthesiologists. *Anesth Analg* 2012; **114**: 46–72
- Webster's Online Dictionary. Available from <http://www.websters-online-dictionary.org/definition/artifact> (accessed 16 March 2013)
- Webster's Online Dictionary. Available from <http://www.websters-online-dictionary.org/definition/resolution> (accessed 16 March 2013)
- Sites BD, Brull R, Chan VW, et al. Artifacts and pitfall errors associated with ultrasound-guided regional anesthesia. Part I: understanding the basic principles of ultrasound physics and machine operations. *Reg Anesth Pain Med* 2007; **32**: 412–8
- Aldrich JE. Basic physics of ultrasound imaging. *Crit Care Med* 2007; **35**: S131–7
- Maecken T, Zenz M, Grau T. Ultrasound characteristics of needles for regional anesthesia. *Reg Anesth Pain Med* 2007; **32**: 440–7
- Chin KJ, Perlas A, Chan VW, Brull R. Needle visualization in ultrasound-guided regional anesthesia: challenges and solutions. *Reg Anesth Pain Med* 2008; **33**: 532–44
- Echo Reflection and Scattering. Available from <http://www.usra.ca/echoreflexion.php> (accessed 16 March 2013)
- US Data for Solids. Available from http://traktor.org/files/sonar/passive_materials/acoustic_impedance_of_some_solids.htm (accessed 16 March 2013)
- Reusz G, Langer CS, Jakab L, Morvay Z. Ultrasound-guided vascular access—the importance of the needle bevel. *Can J Anaesth* 2012; **59**: 499–500

- 16 Brzezinski M, Luisetti T, London MJ. Radial artery cannulation: a comprehensive review of recent anatomic and physiologic investigations. *Anesth Analg* 2009; **109**: 1763–81
- 17 Sites BD, Brull R, Chan VW, et al. Artifacts and pitfall errors associated with ultrasound-guided regional anesthesia. Part II: a pictorial approach to understanding and avoidance. *Reg Anesth Pain Med* 2007; **32**: 419–33
- 18 Saranteas T, Karabinis A. Reverberation: source of potential artifacts occurring during ultrasound-guided regional anesthesia. *Can J Anaesth* 2009; **56**: 174–5
- 19 Ziskin MC, Thickman DI, Goldenberg NJ, Lapayowker MS, Becker JM. The comet tail artifact. *J Ultrasound Med* 1982; **1**: 1–7
- 20 Lichtenstein D, Mézière G, Biderman P, Gepner A, Barré O. The comet-tail artifact. An ultrasound sign of alveolar-interstitial syndrome. *Am J Respir Crit Care Med* 1997; **156**: 1640–6
- 21 Feldman MK, Katyal S, Blackwood MS. US artifacts. *Radiographics* 2009; **29**: 1179–89
- 22 Koyyalamudi VB, Laduzenski S, Boezaart AP, Deitte L. Illusory intravascular needle placement: an unusual ultrasound artifact. *Reg Anesth Pain Med* 2010; **35**: 319–20
- 23 Fornage BD. Sonographically guided core-needle biopsy of breast masses: the “bayonet artifact.” *Am J Roentgenol* 1995; **164**: 1022–3
- 24 Gray AT, Schafhalter-Zoppoth I. “Bayonet artifact” during ultrasound-guided transarterial axillary block. *Anesthesiology* 2005; **102**: 1291–2
- 25 French JL, Raine-Fenning NJ, Hardman JG, Bedford NM. Pitfalls of ultrasound guided vascular access: the use of three/four-dimensional ultrasound. *Anaesthesia* 2008; **63**: 806–13
- 26 Clendenen SR, Robards CB, Clendenen NJ, Freidenstein JE, Greengrass RA. Real-time 3-dimensional ultrasound-assisted infraclavicular brachial plexus catheter placement: implications of a new technology. *Anesthesiol Res Pract* 2010;doi: 10.1155/2010/208025.
- 27 Wong SW, Niazi AU, Chin KJ, Chan VW. Real-time ultrasound-guided spinal anesthesia using the SonixGPS[®] needle tracking system: a case report. *Can J Anaesth* 2013; **60**: 50–3
- 28 Entrekin RR, Porter BA, Sillesen HH, Wong AD, Cooperberg PL, Fix CH. Real-time spatial compound imaging: application to breast, vascular, and musculoskeletal ultrasound. *Semin Ultrasound CT MR* 2001; **22**: 50–64
- 29 Takatani J, Takeshima N, Okuda K, Uchino T, Hagiwara S, Noguchi T. Enhanced needle visualization: advantages and indications of an ultrasound software package. *Anaesth Intensive Care* 2012; **40**: 856–60
- 30 Pagoulatos N, Ma Q, Lundberg AK, Hippe R, Siedenburg CT. Systems and methods for enhanced imaging of objects within an image. United States patent application publication. Available from <http://www.freepatentsonline.com/20110249878.pdf> (accessed 16 March 2013)
- 31 Choudhry S, Gorman B, Charboneau JW, et al. Comparison of tissue harmonic imaging with conventional US in abdominal disease. *Radiographics* 2000; **20**: 1127–35
- 32 Mesurolle B, Bining HJ, El Khoury M, Barhdadi A, Kao E. Contribution of tissue harmonic imaging and frequency compound imaging in interventional breast sonography. *J Ultrasound Med* 2006; **25**: 845–55
- 33 Mesurolle B, Helou T, El-Khoury M, Edwardes M, Sutton EJ, Kao E. Tissue harmonic imaging, frequency compound imaging, and conventional imaging: use and benefit in breast sonography. *J Ultrasound Med* 2007; **26**: 1041–51
- 34 Hocking G, Mitchell CH. Optimizing the safety and practice of ultrasound-guided regional anesthesia: the role of echogenic technology. *Curr Opin Anaesthesiol* 2012; **25**: 603–9
- 35 Souzalnitski D, Lerman I, Halaszynski TM. How to improve needle visibility. In: Narouze SN, ed. *Atlas of Ultrasound-Guided Procedures in Interventional Pain Management*. New York, NY: Springer Science and Business Media LLC, 2011;35–75
- 36 Guo S, Schwab A, McLeod G, et al. Echogenic regional anaesthesia needles: a comparison study in Thiel cadavers. *Ultrasound Med Biol* 2012; **38**: 702–7
- 37 Sviggum HP, Ahn K, Dilger JA, Smith HM. Needle echogenicity in sonographically guided regional anesthesia: blinded comparison of 4 enhanced needles and validation of visual criteria for evaluation. *J Ultrasound Med* 2013; **32**: 143–8
- 38 Stefanidis K, Pentilas N, Dimopoulos S, et al. Echogenic technology improves cannula visibility during ultrasound-guided internal jugular vein catheterization via a transverse approach. *Crit Care Res Pract* 2012;306182. doi: 10.1155/2012/306182
- 39 Perrella RR, Kimme-Smith C, Tessler FN, Ragavendra N, Grant EG. A new electronically enhanced biopsy system: value in improving needle-tip visibility during sonographically guided interventional procedures. *AJR Am J Roentgenol* 1992; **158**: 195–8
- 40 Klein SM, Fronheiser MP, Reach J, Nielsen KC, Smith SW. Piezoelectric vibrating needle and catheter for enhancing ultrasound-guided peripheral nerve blocks. *Anesth Analg* 2007; **105**: 1858–60

Handling editor: R. P. Mahajan